

## Functional MRI of Fingerspelling in Deaf Subjects

Ed Auer<sup>1</sup>, Lynne Bernstein<sup>1</sup>, Jean Moore<sup>1</sup>, Jeong-Won Jeong<sup>2</sup>, Yongxia Zhou<sup>2</sup>, Witya Sungkarat<sup>2</sup>, Manbir Singh<sup>2</sup>

<sup>1</sup>House Ear Institute, 2100 W. Third Street, Los Angeles, CA USA; <sup>2</sup>University of Southern California, OHE-500, University Park, Los Angeles, CA USA;

### Introduction

Fingerspelling is a manual encoding of English orthography used by deaf individuals to communicate English words. Fingerspelling also has several properties that make it useful for studying the cortical processing of language. For example, fingerspelling and speech share the properties of being produced for communication via biological motion. They differ in that fingerspelling represents a socially agreed-upon artificial code, whereas speech is an aspect of the communication system for which humans are biologically predisposed.

We have previously reported on fMRI of lipreading in normal hearing and deaf subjects [1]. Given its function, a complete neuroanatomical model of language processing in deaf individuals should include the cortical sites responsible for reception of fingerspelling. The objective of this study was to investigate the functional neuroanatomy of fingerspelling. A particular issue was the extent to which perception of fingerspelled stimuli share cortical analysis sites with visual speech perception, in light of their shared stimulus properties.

### Methods

Participants in this IRB approved study (N=5) were right-handed young adults with bilateral profound early-onset sensorineural hearing impairments (greater than 95 dB HL, pure tone average across 500, 1000 and 2000 Hz), all with English as their first language and above average screened lipreading performance. At least two experiments were performed per subject—a lipreading experiment and a fingerspelling experiment. In the lipreading experiment, a sequence of silently mouthed monosyllabic words (stimulus 'on') was contrasted with a sequence of colored patterns overlaid on a still frame of the same talker's face (control condition). The subjects pressed a button when two lipread words in sequence were the same and when two patterns in sequence were the same. In the fingerspelling experiment, a sequence of fingerspelled monosyllabic words was similarly contrasted with a sequence of colored shapes overlaid on a still frame of the signer's hand. Possible effect of gradient sound, which was present equally during all conditions, was ignored.

A GE 1.5T EPI Signa Horizon MRI system with its standard quadrature head-coil was used to conduct the fMRI studies. A total of 500 images were acquired from four 10mm thick contiguous transaxial or coronal slices (125 images per slice) covering the auditory regions with TR=4s, effective TE=45ms, 90 deg flip angle, 64x128 acquisition matrix, 20x40cm<sup>2</sup> field-of-view and NEX=1. The first five images per slice were ignored to establish equilibrium and starting at image 6, the task (e.g., lipreading or fingerspelling) and the corresponding control condition were presented in an alternating sequence with 15 images acquired during the task and 15 during the control condition for a total of 4 cycles. The time-series of images was registered using the method described in [2] and analyzed by SPM99 [3] using a box-car reference function delayed by one image to match the hemodynamic response time. Pixels whose z-scores were above a threshold ( $p < 0.001$ ) were color coded and superposed on corresponding anatomy. No threshold was used for cluster size.

### Results

Images during lipreading from two subjects are shown in Figs. 1 and 3 and images during fingerspelling from the same subjects are shown in Figs. 2 and 4. These clearly show common regions of cortical activity while viewing spoken (lipreading) and fingerspelled words (including BA 21, 22, 37, & 39; see yellow boxes in all Figures). In coronal views for four participants, common activity was located in the superior temporal sulcus. In three of five deaf participants, several dorsolateral parietal areas were strongly activated by viewing fingerspelled words (BA 7; see green boxes in Figs. 2 and 4).

### Conclusions

Fingerspelled and silently spoken words (lipreading) resulted in common regions of cortical activation in deaf perceivers. These regions are consistent with regions observed in studies of both spoken and signed language [1,4,5]. In some participants, fingerspelled words resulted in additional areas of activation including several dorsolateral

parietal areas. It is likely that parietal activation is non linguistic, as similar activation has been observed for viewing goal-directed hand-motions [6]. Individual subject differences likely represent different processing strategies due to nonlinguistic task characteristics.

### References

1. Bernstein L. et al: Proc. ISMRM, 328, 2000.
2. Singh M. et al: IEEE Trans Nucl Sci, 45, 2162-2167, 1998.
3. Friston K. et al: Human Brain Mapping, 2, 189-210, 1995.
4. Binder, J. et al., Brain, 119, 1239-1247 (1996).
5. Neville H. et al., Proc. Natl. Acad. Sci., 95, 922-929 (1998).
6. Bonda E. et al., J. Neurosci., 16(11), 3737-3744 (1996).

### Acknowledgment

This work is supported in part by the House Ear Institute, and grants NIH NIDCD DC03633 and NIH P50 AG05142.

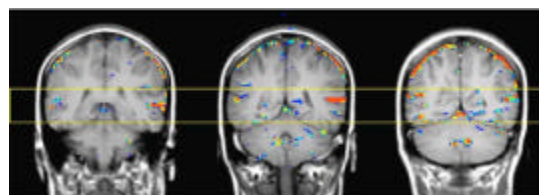


Fig 1. Three 10mm thick contiguous coronal slices showing regions activated during lipreading for subject 1.

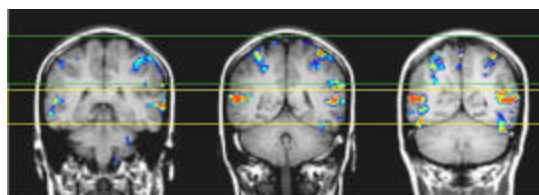


Fig 2. Three 10mm thick contiguous coronal slices showing regions activated during fingerspelling for subject 1.

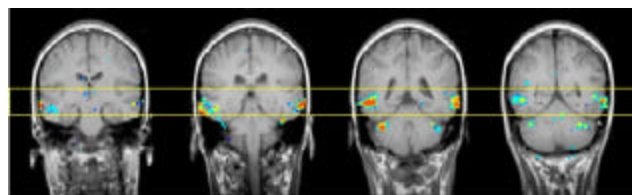


Fig 3. Four 10mm thick contiguous coronal slices showing regions activated during lipreading for subject 2.

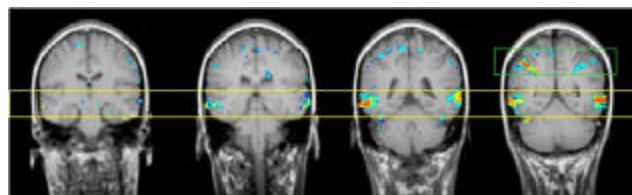


Fig 4. Four 10mm thick contiguous coronal slices showing regions activated during fingerspelling for subject 2.